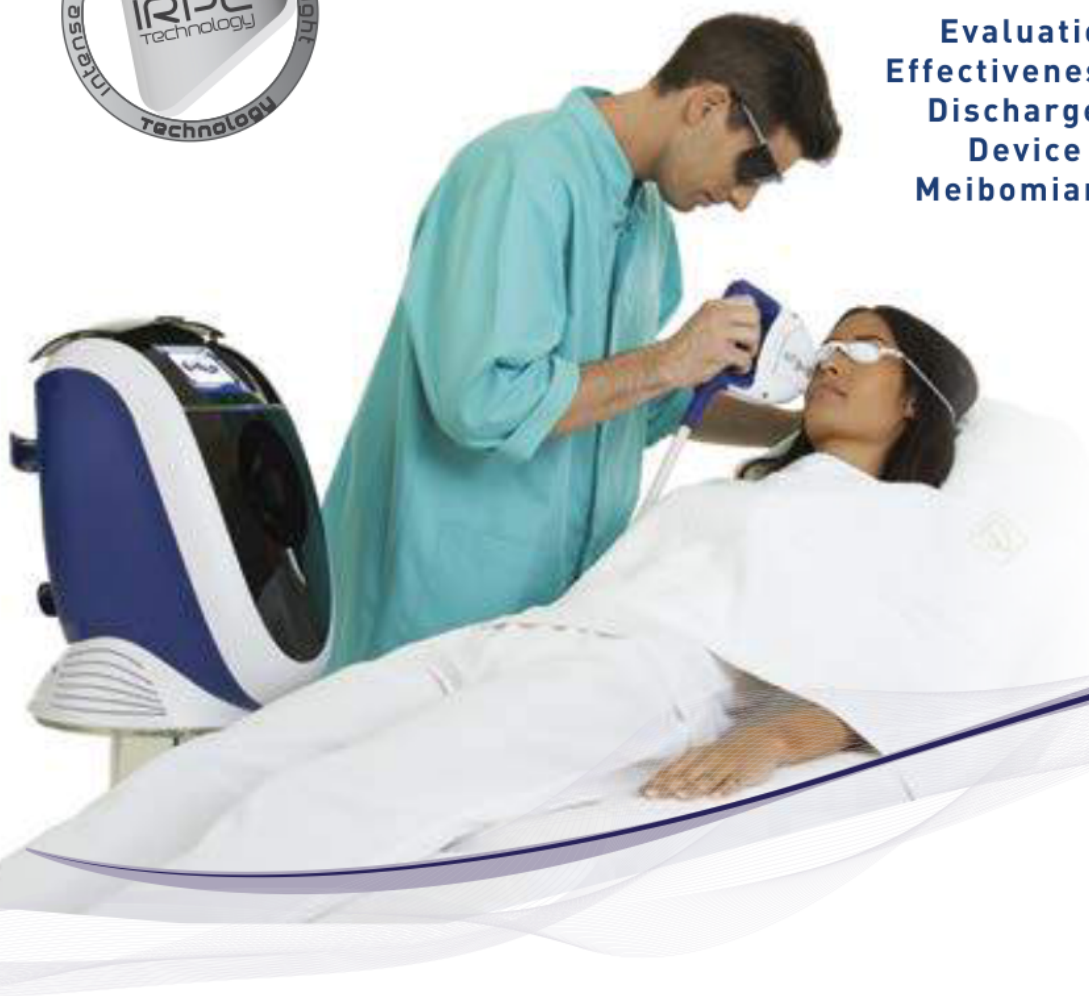

E-Eye

CLINICAL STUDIES

July 2014 – October 2014
Third Hospital of Pekin University

Evaluation of the Safety and Effectiveness of the Controlled Discharge Xenon Flash Lamp Device in the Treatment of Meibomian Gland Dysfunction Caused Dry Eye



E-Swin

PREMIER FABRICANT FRANÇAIS DE HAUTES TECHNOLOGIES DE LUMIÈRE

THE PURPOSE OF THE STUDY

The chronic inflammatory ocular surface dry eye, which caused by meibomian gland dysfunction is very common in clinic. The purpose of this study is to evaluate a new method -- Controlled Discharge Xenon Flash Lamp Device in the treatment of dry eye syndrome caused by meibomian gland dysfunction, the effectiveness and the safety.

METHOD

1. EQUIPMENT:

E-Eye machine was provided by E-Swin, France (www.e-swin.com).

2. PATIENTS:

Patients were enrolled into the study from July 2014 to October 2014, at the Third Hospital of Peking University. The criteria for enrollment and exclusion were shown in Table 1. For diagnosis, the dry eye syndrome should have lasted for at least 12 months, and the tear film break-up time (TBUT) should be less than 10s, while the meibomian gland orifice obstruction should be greater than or equal to grade 1. For the treatment group, all patients had 4 visits, first visit, 2 weeks, 1 month and 2 month after first visit. The Controlled Discharge Xenon Flash Lamp Device was applied to the patient at each visit (energy 13.0J/cm²).

Table 1: General criterion for enrollment and exclusion of the study

Enrollment	Exclusion
Age between 18-80 years old.	Informed consent.
Diagnosis of dry eye patients with meibomian gland orifice obstruction over grade 1.	Severe ocular surface disease history or the history of ocular inflammation (with the exception of keratoconjunctivitis sicca).
Able to cooperate with researchers.	Had ocular surgery within 1 year of time
Informed consent.	History of ocular drug use within 1 month of time (not including the preservative free artificial tears); Open wound near meibomian gland; History of systemic anti-inflammatory drug use within 3 month of time.

3. CLINICAL EVALUATION:

Clinical evaluation including (1) assessment of dry syndrome, (2) eyelid (palpebral blunt, notch, vascular abnormalities, eyelash abnormalities, hyperkeratosis, front blepharitis), (3) meibomian gland (quantity at central 1cm, degree of obstruction, scar, deletion of orifice, nature of the secretion), (4) tear film (BUT, debris, tear foam, the height of the upper and lower tear river), (5) cornea and conjunctiva (conjunctival hyperemia, conjunctival flabby, corneal staining).

4. STATISTICS:

For evaluation of the symptom, meibomian gland (central 1cm quantity, degree of obstruction, deletion, glandular secretion, tear film (BUT), debris, tear foam, the height of upper and lower tear river), cornea and conjunctiva (conjunctival congestion, corneal staining, conjunctival relaxation), the scores were analyzed using the paired test. For evaluation of eyelid (eyelid blunt, notch, vascular abnormalities, eyelash abnormalities, hyperkeratosis, front blepharitis) and meibomian gland (scar), chi-square test was used.

RESULTS

1. DEMOGRAPHIC CHARACTERISTICS:

The study evaluated 40 dry eye patients with 80 eyes, including 22 female patients (44 eyes) and 18 male patients (36 eyes). The mean age of patients was 51.3± 20.1 years old (ranged 21-78 years old).

2. SYMPTOM ASSESSMENT:

Table 2: Effectiveness of controlled discharge xenon flash lamp device therapy.

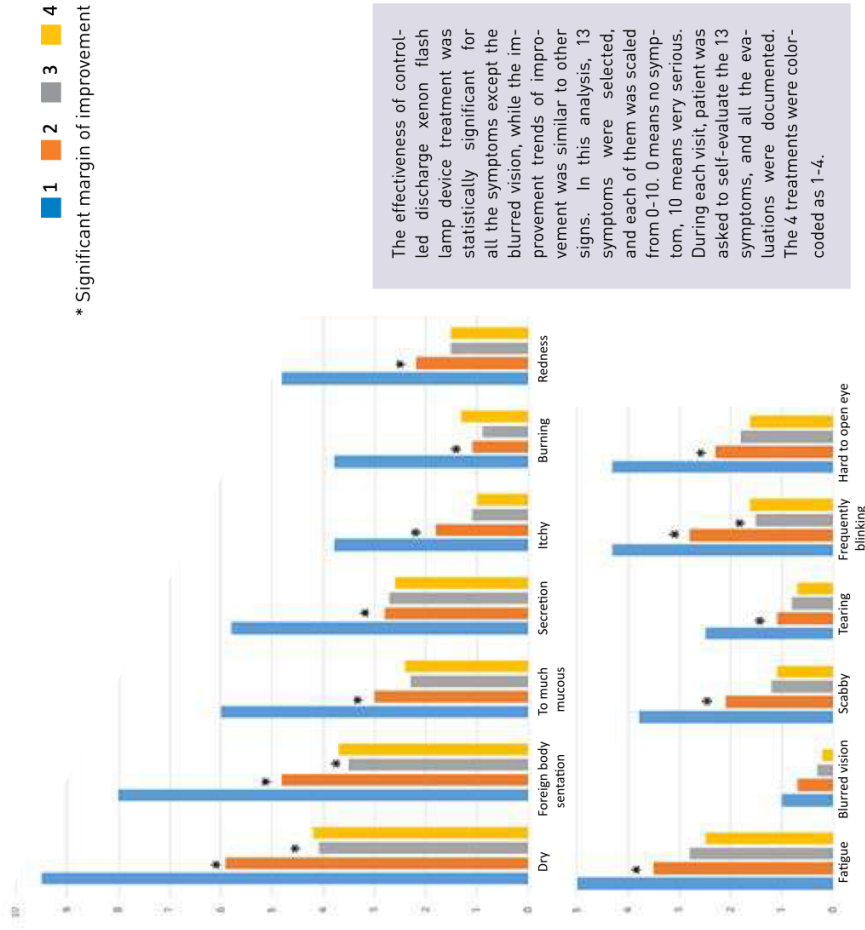
Symptom	Prior to the 1 st treatment on day 0	Prior to the 2 nd treatment on day 15	Prior to the 3 rd treatment on day 30	Prior to the 4 th treatment on day 60
Dryness	9.5±2.2	5.9±3.5	4.1±3.1	4.2±3.0
P		<0.01	<0.01	0.71
Foreign Body Sensation	8.0±4.1	4.8±3.9	3.5±3.4	3.7±3.2
P		<0.01	0.03	0.79
Excessive Mucus	6.0±5.0	3.0±3.4	2.3±3.2	2.4±3.7
P		<0.01	0.13	0.73
Secretions from Eye Corner	5.8±5.0	2.8±3.3	2.7±3.4	2.6±3.8
P		<0.01	0.08	0.95
Itch	3.8±4.9	1.8±3.4	1.1±2.6	1.0±2.6
P		<0.01	0.21	0.63
Burning Sensation	3.8±4.9	1.1±2.8	0.9±2.5	1.3±2.8
P		<0.01	0.48	0.36
Redness	4.8±5.1	2.2±3.4	1.5±2.7	1.5±2.8
P		<0.01	0.16	0.87
Redness	5.0±5.1	3.5±4.0	2.8±3.4	2.5±3.4
P		<0.01	0.06	0.37
Vision	1.0±3.1	0.7±2.2	0.3±1.5	0.2±0.9
P		0.16	0.24	0.57

Symptom	Prior to the 1 st treatment on day 0	Prior to the 2 nd treatment on day 15	Prior to the 3 rd treatment on day 30	Prior to the 4 th treatment on day 60
Scar on Eyelash	3.8±4.9	2.1±3.1	1.2±2.5	1.1±2.4
P		<0.01	0.27	0.88
Wind Tearing	2.5±4.4	1.1±2.8	0.8±2.4	0.7±1.9
P		<0.01	0.52	0.52
Frequent Blinking	4.3±5.0	2.8±3.9	1.5±2.7	1.6±3.1
P		0.01	0.01	0.65
Morning Open Difficulties	4.3±5.0	2.3±3.4	1.8±3.1	1.6±2.8
P		0.01	0.27	0.6

CONCLUSION

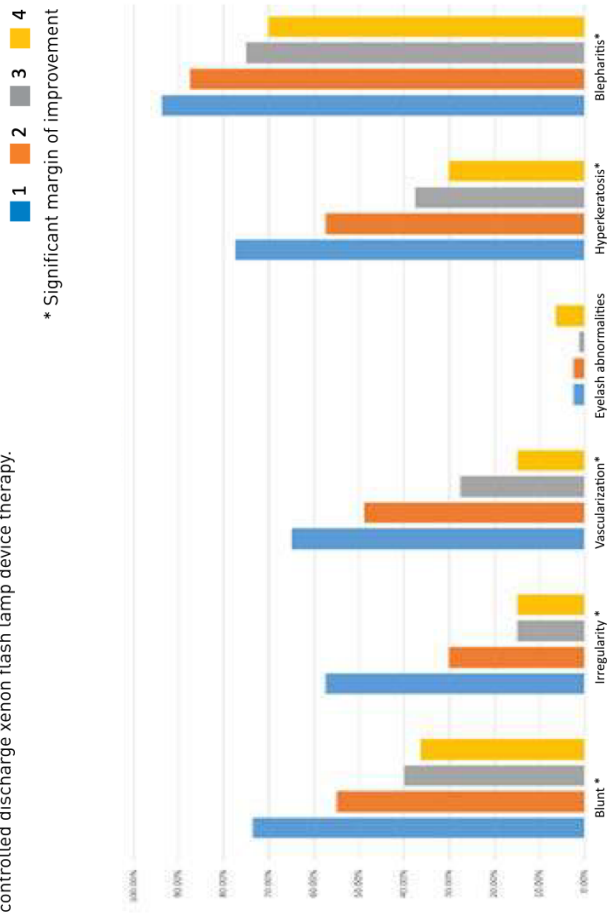
Using Controlled Discharge Xenon Flash Lamp Device treatment (Energy Level:13.0J/cm2), the dry eye symptoms were significantly relieved in patients suffered with meibomian gland dysfunction caused dry eye, and the morphology of the palpebral margin, meibomian gland opening obstruction, and meibomian gland quantity were also improved. All the difference between prior and post treatment was statistically significant. In addition, the Controlled Discharge Xenon Flash Lamp Device therapy could improve the tear film quality, and prolonged the tear-breakup time. Following 4 consecutive treatments, the improvement to the dry eye symptom and the sign of the ocular tissues could be well maintained. Overall, this study had demonstrated that the Controlled Discharge Xenon Flash Lamp Device treatment is safe and effective in the treatment of dry eye caused by meibomian gland dysfunction.

Figure 1: Effectiveness of controlled discharge xenon flash lamp device therapy.



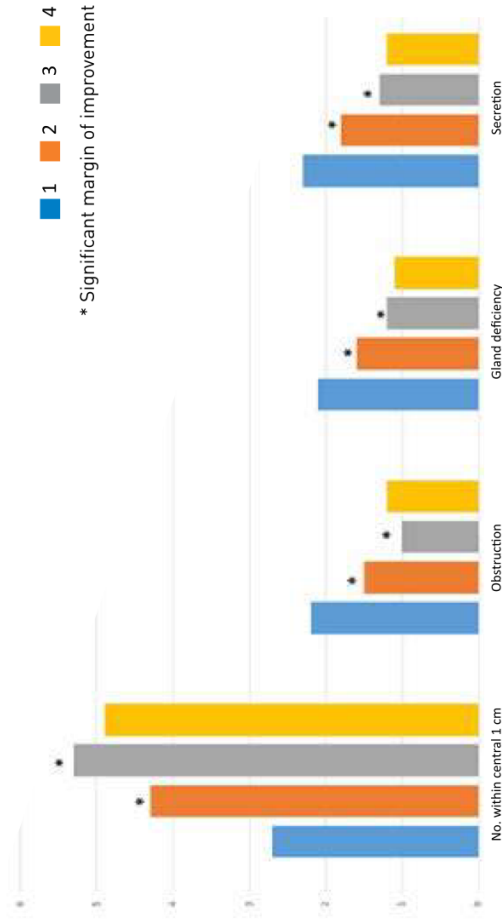
The effectiveness of controlled discharge xenon flash lamp device treatment was statistically significant for all the symptoms except the blurred vision, while the improvement trends of improvement were similar to other symptoms. In this analysis, 13 symptoms were selected, and each of them was scaled from 0-10. 0 means no symptom, 10 means very serious. During each visit, patient was asked to self-evaluate the 13 symptoms, and all the evaluations were documented. The 4 treatments were color-coded as 1-4.

2. EVALUATION OF THE CLINICAL SIGNS:
Figure 2: Effect to the signs of the Palpebral Margin by the controlled discharge xenon flash lamp device therapy.



Effectiveness of the controlled discharge xenon flash lamp device therapy to the signs of the palpebral margin. The scale was set as 0 or 1. The 0 means no signs of the palpebral margin, 1 means it has the signs. The percentage of the patients with the signs of the palpebral margin was demonstrated from Y-axis.

Figure 3: Effect to the signs of the Meibomian Gland by the controlled discharge xenon flash lamp device therapy.



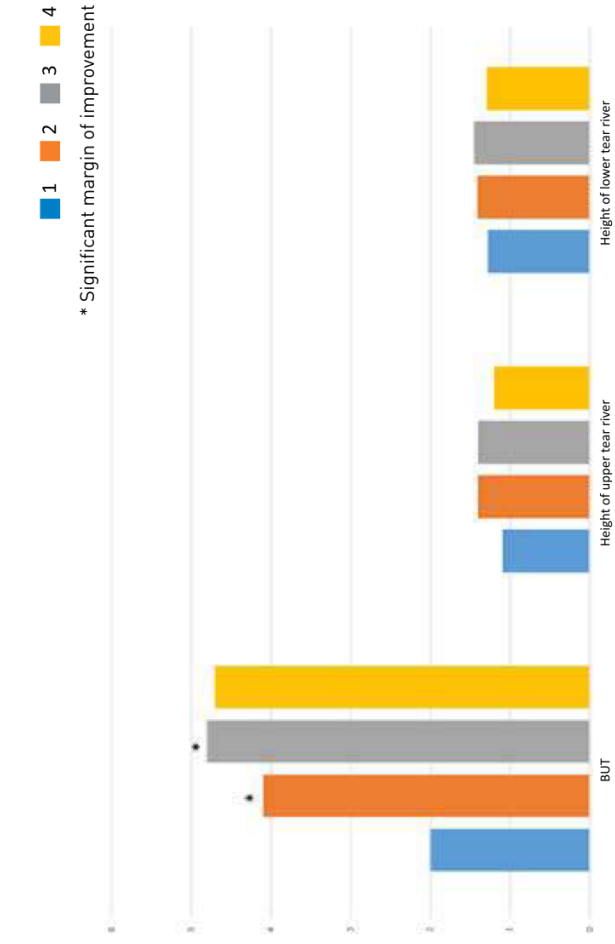
Note: (1) The number of the Meibomian Gland (central 1 cm) was counted under a slit lamp; (2) the level of the obstruction of the Meibomian Gland was assessed by manually pressing the Meibomian Gland, and observing the easiness of the secretion coming out. The scale was set from 0 to 3 (see the table below).

0	Easily expressed
1	Expressed with mild pressure
2	Expressed with moderate pressure
3	Meibum not expressible, even with hard pressure

(3) to the nature of the secretions from the Meibomian Gland, the scale was set from 0 to 3 (see the table below).

0	Clear fluid
1	Cloudy fluid
2	Cloudy particulate fluid
3	Inspissated, like toothpaste

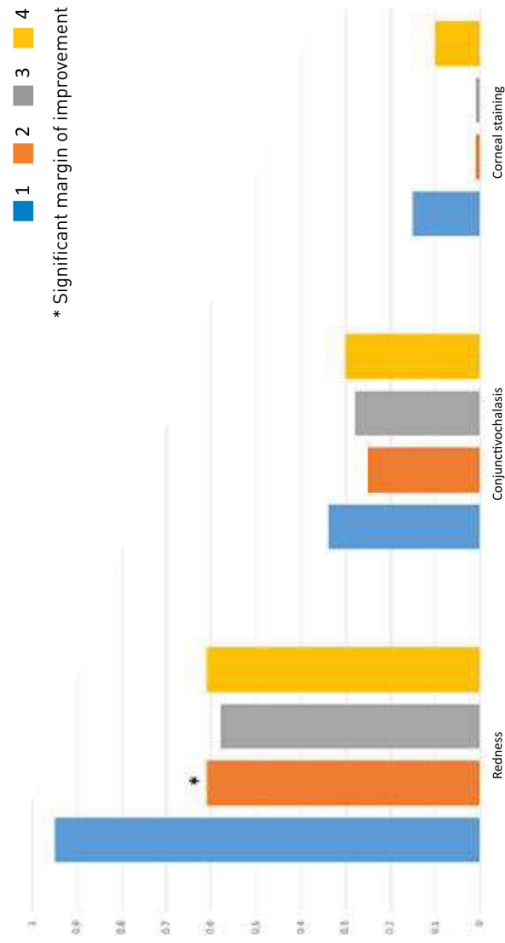
Figure 4: Effect to the Signs of the Tear Film by the controlled discharge xenon flash lamp device therapy.



Effect to the signs of the Tear Film by the controlled discharge xenon flash lamp device therapy. The result indicated that the treatment significantly extended the tear film break-up time, but no effect to the height of both upper and lower tear river.

Note: The height of upper tear river and lower tear river is 0.1mm.

Figure 5: Effect to the signs of the Cornea and Conjunctiva by the controlled discharge xenon flash lamp device therapy.



Effect to the signs of the Cornea and Conjunctiva by the controlled discharge xenon flash lamp device therapy. The results indicated that conjunctivochalasis and corneal staining was not changed by the therapy, but the redness of conjunctiva was significantly reduced following the controlled discharge xenon flash lamp device therapy.

Note: For redness, conjunctivochalasis and corneal staining, the scale was set as 0-3. 0 means no sign, 3 means the sign was very serious. The scale was 0-1 on Y-axis, since all the patients enrolled in this study had limited (<1) signs of redness, conjunctivochalasis and corneal staining.

Join the IRPL[®] technology innovation

E>EYE



For further information on the E>EYE, please visit:
www.e-swin-pro.com

call us:
+33 1 30 46 37 68 (international number)

or email us:
commercial@e-swin-pro.com

www.e-swin-pro.com

